

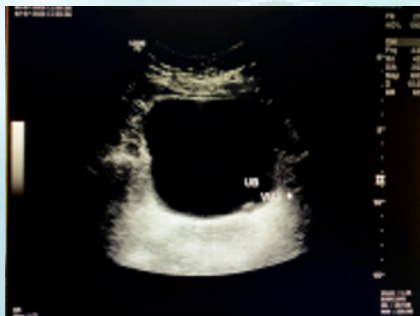LEIOMYOMA BLADDER

Dr M. Ramalingam M.S., M.Ch., D.NB (Uro); FRCS (Edin)
LAPAROSCOPY & TRANSPLANT SURGEON
UROLOGY CLINIC, HINDUSTHAN HOSPITAL
COIMBATORE

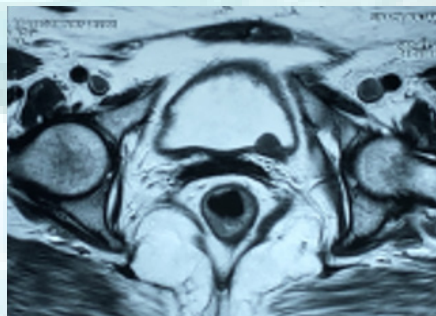


A 50 years old female presented with pain lower abdomen, increased frequency and dysuria for 6 months. Clinically examination was unremarkable. Her urine cultures were sterile. Ultrasound abdomen revealed a single 2x1cm lesion in the left posterior wall near the ureteric orifice which was confirmed by CECT and MRI. She underwent Transurethral resection (TUR) of the tumor.

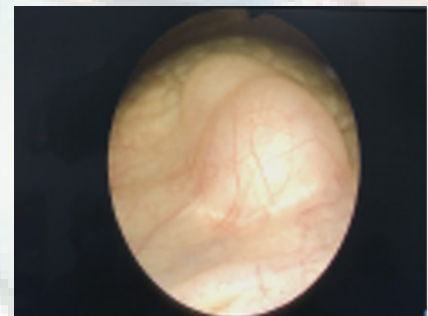
The histopathology examination revealed leiomyoma of bladder confirmed by immunohistochemistry. Bladder Leiomyoma is a rare benign tumor arising from the smooth muscle of the bladder which can present as painless hematuria or lower urinary tract storage symptoms. Transurethral resection in smaller tumors and laparoscopic partial cystectomy in larger lesions is curative. Diagnosis of this condition requires Immunohistochemistry. Though a benign tumor, regular follow up of the patient is necessary.



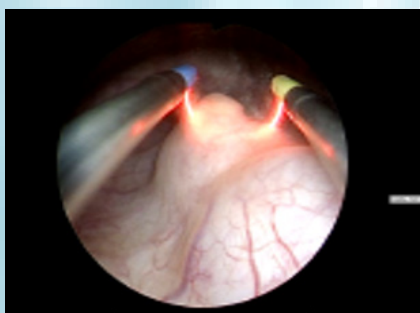USG showing



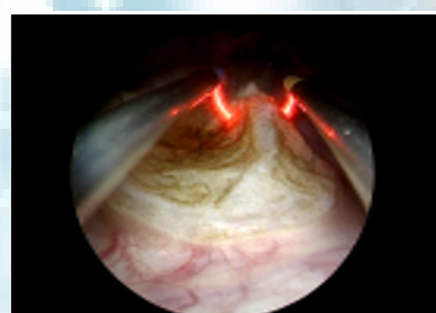MRI showing smooth tumour



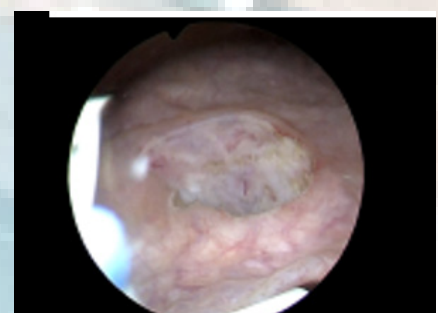
Cystoscopic of tumour



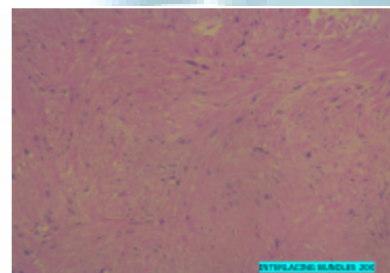
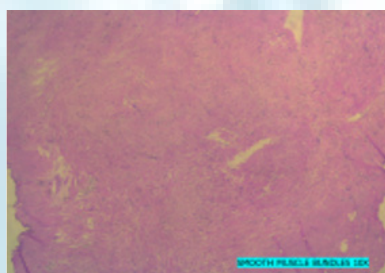
TUR of tumour



TUR of tumour in progress



TURBT completed



HPE of Leiomyoma